Journal of Zoo and Wildlife Medicine 33(1): 8–15, 2002

CLINICOPATHOLOGIC FEATURES OF SUSPECTED BREVETOXICOSIS IN DOUBLE-CRESTED CORMORANTS (*PHALACROCORAX AURITUS*) ALONG THE FLORIDA GULF COAST

Christine Kreuder, V.M.D., M.P.V.M., Jonna A. K. Mazet, D.V.M., Ph.D., Gregory D. Bossart, V.M.D., Ph.D., Tim E. Carpenter, Ph.D., Marcel Holyoak, Ph.D., Marc S. Elie, D.V.M., A.C.V.I.M., and Scott D. Wright, Ph.D.

Abstract: Outbreaks of morbidity and mortality in double-crested cormorants (*Phalacrocorax auritus*) along Florida's Gulf Coast have occurred sporadically for at least 30 yr. During these outbreaks, the Clinic for the Rehabilitation of Wildlife, located on Sanibel Island in Florida, has admitted a substantial number of cormorants with consistent presentation of primarily neurologic clinical signs. In order to investigate the association of these outbreaks in cormorants with exposure to brevetoxin, we compared the timing of admittance of cormorants with outbreak-specific clinical signs to blooms of the brevetoxin-producing marine algae, *Karenia brevis* (formerly *Gymnodinium breve*), around Sanibel Island from 1995 through 1999. The clinic admitted 360 out of 613 cormorants with the common clinical sign of severe cerebellar ataxia in six outbreaks occurring during this period. The ataxia was characterized by a broad-based stance, truncal incoordination, hypermetric gait, and intention tremors of the head. The histopathologic findings in 10 cormorants euthanized in 1997 were mild and nonspecific. An immunohistochemical staining technique for the detection of brevetoxin in cormorants documented the uptake of brevetoxin in tissues from four cormorants admitted during an outbreak in 1997, but a modified technique used on samples from 11 cormorants admitted during a *K. brevis* bloom in 2000 produced indeterminate results. Admittance of cormorants with outbreak-specific clinical signs was positively correlated ($P < 0.05$) with concurrent concentrations of *K. brevis* in local water. The cross-correlation coefficient was also significant when increased *K. brevis* levels preceded cormorant admittances by 2, 4, 6, and 8 wk. This delay in time between *K. brevis* blooms and cormorant admittance and our clinical finding of neurologic abnormalities in cormorants without overt histopathologic features suggest an association between *K. brevis* blooms and local cormorant morbidity.

Key words: Red tide, *Karenia brevis*, brevetoxin, double-crested cormorant, *Phalacrocorax auritus*, neurologic disease.

INTRODUCTION

Harmful algal blooms may be both a consequence and a cause of marine ecologic disturbances with major environmental, public health, and economic significance.[4,6] Blooms of the marine dinoflagellate *Karenia brevis* (formerly *Gymnodinium breve*) are often called red tides and have long been associated with extensive fish kills in the Gulf of Mexico.[8,12,17] *Karenia brevis* produces polyether neurotoxins called brevetoxins, which have well-described chemical and experimental pharmacologic properties.[1] Brevetoxins and brevetoxin-like marine toxins occur worldwide and are suspected to have a detrimental effect on many marine animals.[9–12] However, this effect was difficult to document until an immunohistochemical staining technique was developed to identify brevetoxin in the tissues of manatees.[2]

In 1996, West Indian manatees (*Trichechus manatus longirostris*) along the southwest coast of Florida experienced an unprecedented mortality event that coincided with a substantial local *K. brevis* bloom. The immunohistochemical staining technique correlated brevetoxin with multiple histopathologic lesions in exposed manatees, suggesting possible pathogenic mechanisms for brevetoxicosis.[2]

Outbreaks of morbidity and mortality in double-crested cormorants (*Phalacrocorax auritus*) have coincided with manatee mortality and *K. brevis* blooms along the southwest coast of Florida.[8,11] The Clinic for the Rehabilitation of Wildlife (CROW), located on Sanibel Island in Lee County, Florida, receives wild animals from the area of southwest

From the Wildlife Health Center, School of Veterinary Medicine, University of California, One Shields Avenue, Davis, California 95616, USA (Kreuder, Mazet); Harbor Branch Oceanographic Institution, Fort Pierce, Florida 34946, USA (Bossart); the Department of Medicine and Epidemiology, School of Veterinary Medicine, University of California, Davis, California 95616, USA (Carpenter); the Department of Environmental Science and Policy, University of California, Davis, California 95616, USA (Holyoak); Cardiopet Veterinary Referral Centre, Little Falls, New Jersey 07427, USA (Elie); and Florida Fish and Wildlife Conservation Commission, Florida Marine Research Institute, St. Petersburg, Florida 33701, USA (Wright). Correspondence should be directed to Dr. Kreuder.

Florida that has often had increased marine animal mortality during *K. brevis* blooms.[2,11,12] Over the past 30 yr, CROW has admitted many cormorants with a consistent presentation of neurologic clinical signs over relatively short periods of time. Establishing a definitive diagnosis during these outbreaks was difficult because the histopathologic, virologic, and bacteriologic results from affected cormorants failed to reveal a common etiology. Also, sporadic monitoring of *K. brevis* levels locally did not provide an appropriate context within which to evaluate the temporal patterns of morbidity and mortality events in cormorants.

Linking cormorant morbidity to local *K. brevis* blooms is difficult for several reasons. Although monitoring the spatial and temporal distribution of *K. brevis* concentrations along the southwest coast of Florida has intensified over the past 5 yr, algal blooms are extremely patchy in nature and counts of dinoflagellates may correlate poorly to the actual brevetoxin levels in water. Also, these coastal birds can fly considerable distances away from the focus of a red tide before they become moribund. Moreover, the presence of a red tide is not always correlated with highly toxic biotoxins because there are several types of brevetoxin that have varying degrees of toxicity. Brevetoxin is not released into the local water until algal cells die and lyse. Given that *K. brevis* blooms occur regularly and with varying intensity, cormorants are likely to become clinically affected only after their toxin burden has surpassed some unknown threshold, potentially through both acute and chronic exposure. Furthermore, the mechanism of biotoxin accumulation and clearance in cormorants is unknown. Because cormorants are fish-eating marine birds, they may be exposed to brevetoxin through ingestion as well as inhalation, the latter of which has been documented in manatees.[2] The potential for gradual bioaccumulation in prey items and subsequent trophic transfer of brevetoxin to cormorants suggests that there may be a time delay in the reported algal blooms and the outbreaks in cormorants. Finally, clinical and pathologic findings associated with brevetoxin exposure have not been documented in detail in avian species.

Evaluating the link between cormorant morbidity and *K. brevis* blooms is important to understand the impact of harmful algal blooms on the southwest Florida marine ecosystem. We report herein the common clinical and histopathologic features found in cormorants during a major outbreak of morbidity in 1997, brevetoxin-specific immunohistochemical staining results in cormorants, and the association between cormorant morbidity with specific clinical signs and *K. brevis* concentrations in local waters from 1995 through 1999. We hypothesize that if cormorants are experiencing brevetoxicosis in southwest Florida, clinical and histologic features will reflect acute or chronic (or both) neurotoxin exposure, immunohistochemical staining features for exposed cormorants will be similar to those seen in exposed manatees, and *K. brevis* levels in local waters will be correlated with subsequent epidemics in cormorants.

MATERIALS AND METHODS

CROW (Sanibel, Florida, USA) received 613 double-crested cormorants from 1 January 1995 to 31 December 1999. Debilitated cormorants were admitted to the clinic after being recovered from the coastal and inland areas within approximately 40 km of Sanibel Island (26°25′N, 82°7′W). Detailed clinical evaluations, body weight measurements, and basic hemograms were performed on cormorants at the time of admission to the center. Blood was drawn from the ulnar vein using a 25-gauge needle, immediately transferred to heparinized microhematocrit tubes (Chase Scientific Glass, Rockwood, Tennessee 37748, USA), and centrifuged for 3 min at 10,400 rpm. The packed cell volume (PCV) was measured using a hematocrit reading scale (Sherwood Medical, St. Louis, Missouri 63103, USA), which quantifies red blood cells as a percent of whole blood. Total solids (TS) in the centrifuged plasma were measured using a Reichert refractometer (American Optical, Buffalo, New York 14240, USA). The cormorants were classified as mature or immature on the basis of their plumage characteristics and eye color. The staff veterinarian performed thorough neurologic examinations on all admitted cormorants to identify birds with outbreak-specific clinical signs. Specifically, general mental status, gait, stance, head position, and ocular motility (presence of spontaneous nystagmus) were evaluated on admission. Birds were classified as having outbreak-specific clinical signs if they exhibited ataxia and intention tremors of the head without clinical evidence for another cause of these signs, such as head trauma. Other outbreak-specific clinical signs included vertical positional nystagmus, hypermetric gait, and broad-based stance. Birds were euthanized by intravenous sodium pentobarbital administration (110 mg/kg i.v.) if physical examination and hematologic findings supported a grave prognosis. Recovered cormorants were released once they were fully ambulatory, fully flighted, and had regained a body weight of at least 1.8 kg by self-feeding.

Body weight (n = 42), PCV (n = 33), and TS

(n = 33) of cormorants exhibiting outbreak-specific clinical signs on admission from September through mid-November 1997 during a *K. brevis* bloom were compared with those of cormorants admitted to the clinic with trauma from September through mid-November 1998 (n = 25), a time period without a known *K. brevis* bloom. Cormorants were matched on season of admittance to reduce the seasonal differences in body weight, PCV, and TS. Cormorants admitted with evidence of systemic disease were excluded from the control group because they were expected to have more substantial body weight and hematologic abnormalities as a result of their primary condition than do cormorants admitted because of trauma. A Mann–Whitney *U*-test was used to compare the two groups for significant differences. A nonparametric procedure was chosen because the PCV and TS values were not normally distributed and the 1998 control group had a low sample size. The proportion of immature cormorants admitted with outbreak-specific clinical signs was compared with the proportion of immature cormorants admitted for all other reasons from 1995 through 1999 by the chi-square test for independence. Similarly, the proportion of released cormorants admitted with outbreak-specific clinical signs was compared with the proportion of released cormorants admitted for all other reasons from 1995 through 1999 by the chi-square test for independence. All statistical tests were performed using statistical software (SPSS Base 10.0, SPPS Inc., Chicago, Illinois 60606, USA), and differences between groups were determined to be significant using a two-tailed test for significance at a level of $P \leq 0.05$.

In order to determine a diagnosis for the clinical syndrome, detailed histopathologic examinations were performed on 10 cormorants with outbreak-specific clinical signs, which were euthanized within hours of arrival in 1997. Brain, heart, spleen, liver, kidney, lung, trachea, proventriculus, small intestine, large intestine, and pancreas were placed in 10% neutral buffered formalin, embedded in paraffin once fixed, sectioned at 5 μm, and stained with hematoxylin and eosin for examination by light microscopy. To document brevetoxin exposure in cormorants, a biotin-avidin–enhanced immunohistochemical stain with a polyclonal primary antibody to brevetoxin[2] was used to examine tissues from four cormorants with outbreak-specific clinical signs, which were euthanized during a *K. brevis* bloom in 1997, and 11 cormorants that were euthanized or died during a *K. brevis* bloom in 2000. The assay was modified to eliminate nonspecific background staining by a blocking step with normal serum for use on the cormorant samples obtained in 2000. Heart, brain, lung, trachea, and spleen were mounted in paraffin blocks and cut at 5 μm. The tissues were placed on charged slides, deparaffinized, and put through an endogenous peroxidase-inhibition procedure. The slides were then stained using a labeled strepavidin biotin (LSAB+) immunohistochemical staining kit (DAKO Corp., Carpinteria, California 93013, USA). The tissues were incubated overnight at 4°C with primary goat anti-brevetoxin antibody (Dan Baden, University of North Carolina, Wilmington, North Carolina 28409, USA) at a working dilution of 1:150. A DAB (3,3′-diaminobenzidine tetrahydrochloride) Chromagen solution (DAKO Corp.) was used for coloration, and hematoxylin was used as a counterstain. Manatee lymph node containing brevetoxin was used as a positive control, and human tonsil was used as a negative control. Slides were classified as positive if they contained strongly immunoreactive cells.

The timing of clinic admittance of cormorants with outbreak-specific clinical signs was compared with the timing of local *K. brevis* blooms from 1995 through 1999 using time series analysis techniques. Because *K. brevis* blooms are extremely patchy, brevetoxin exposure in cormorants was estimated by calculating an algal index for each 2-wk period from 1 January 1995 to 31 December 1999. *Karenia brevis* concentrations in cells per liter of seawater were measured around Sanibel Island (26°40′ to 26°62′N) in the areas in which cormorants were recovered. A total of 649 measurements were made at an approximate frequency of once per week as part of a large-scale project conducted by the Florida Fish and Wildlife Conservation Commission, the Department of Agriculture and Consumer Services, and the Shellfish Environmental Assessment Section. The concentration of *K. brevis* cells per liter was determined by hand counting under a dissecting scope.[14] Each *K. brevis* measurement was reported as a range, and the midpoint of this range was used to estimate the *K. brevis* level. An algal index for each 2-wk period was calculated as the $\log_{10}$ of 1 + the mean value of all measurements during that 2-wk period. Two-week intervals without measurements of *K. brevis* were excluded from the analysis. The number of cormorants admitted to the clinic with brevetoxin-specific clinical signs was summed for each 2-wk period from 1 January 1995 to 31 December 1999 in order to compare the temporal distribution of cormorant admittances with the algal index. The temporal relationship between the cormorants with outbreak-specific signs and the algal index was measured by cross-correlation coefficients[3] (R_{xy}) calculated using

statistical software (Statistica for Windows, StatSoft Inc., Tulsa, Oklahoma 74104, USA). This method correlates the number of cormorants with outbreak-specific signs with the time-lagged values of algal index to evaluate an appropriate time delay in the effect of *K. brevis* blooms on cormorant admittance. Cross-correlation coefficients were calculated for one to ten 2-wk forward time lags and were determined to be statistically significant at $P \leq 0.05$.

RESULTS

The clinic admitted 360 (58.7%) cormorants with outbreak-specific clinical signs out of a total of 613 cormorants admitted from 1995 through 1999. The clinical finding common to all cormorants categorized as having outbreak-specific clinical signs was severe cerebellar ataxia. The ataxia was characterized by a broad-based stance, truncal incoordination, hypermetric gait, and intention tremors of the head. Stimuli, such as patient handling, often resulted in exaggerated responses and hyperactivity. Positional vertical nystagmus was also noted in approximately half of the ataxic cormorants. The ataxia typically lasted for 2–4 days, and cormorants with a good-to-fair prognosis on admission (based on body weight, hematologic values, and the absence of concurrent injury or disease) generally responded to supportive care. Most (78.7%) cormorants admitted with outbreak-specific clinical signs were of immature age, which was significantly higher than the proportion of immature cormorants (57.6%) among those admitted for all other reasons ($X^2 = 28.6$, $P < 0.001$). The odds of an immature cormorant's being admitted with outbreak-specific clinical signs was 2.72 times that of an adult. A total of 125 (34.7%) cormorants with outbreak-specific clinical signs were released 4–8 wk after admission, whereas a total of 60 (23.7%) cormorants without outbreak-specific clinical signs were released. The released proportion of cormorants with outbreak-specific signs was statistically significantly higher than the released proportion of cormorants without outbreak-specific clinical signs ($X^2 = 8.54$, $P = 0.003$).

For cormorants admitted with outbreak-specific clinical signs from September through mid-November 1997 ($n = 42$), the mean body weight was 1.20 kg. Cormorants were considered to be anemic if their PCV was ≤20% and hypoproteinemic if their TS was ≤2.0 mg/dl. On the basis of these criteria, 42.4% ($n = 14$) of the outbreak cormorants were anemic and 60.6% ($n = 20$) were hypoproteinemic. The body weight, PCV, and TS values did not differ significantly between outbreak cormorants admitted during a *K. brevis* bloom and cormorants admitted with trauma in the absence of a *K. brevis* bloom ($P = 0.542$, 0.277, and 0.489, respectively).

Similar to the findings noted in the previous years, necropsy of cormorants admitted with outbreak-specific signs from 1995 through 1999 failed to reveal a specific cause of death or explanation of the clinical signs. Endoparasitism was a common finding in necropsied cormorants. *Contracaecum* spp. and *Tetramera* spp. were identified grossly in the proventriculus. Trematodes were identified microscopically in the kidneys and, occasionally, in the small intestine and pancreas. Histopathologic findings in the 10 cormorants euthanized in 1997 were generally nonspecific and insignificant. Mild pulmonary hemorrhage and congestion were commonly noted ($n = 8$) but were thought to be associated with acute agonal cardiovascular collapse. Other frequent findings included hepatic and splenic hemosiderosis ($n = 10$), as well as chronic, mild cholangitis and nephritis ($n = 9$). None of these findings were determined to be severe enough to be the primary cause of death. No brain or brain stem lesions were found.

The immunohistochemical staining technique documented brevetoxin uptake in each of the four cormorants admitted with outbreak-specific clinical signs in 1997. Brevetoxin was distributed in lymphoid cells of the spleen and in macrophages of the spleen and lung in all cormorants examined. Other immunoreactive tissues included tracheal mucosa (2/3 of those examined), heart (1/2 of those examined), and brain (1/4 of those examined). Mild background staining because of the incomplete inhibition of the endogenous peroxidase was evident in all stained slides. However, samples from cormorants admitted in 1997 showed an immunostaining pattern and cell tropism similar to that seen using this technique on manatees with brevetoxicosis during the 1996 outbreak.[2] This technique, modified to block nonspecific background staining, produced equivocal evidence of brevetoxin deposition in tissues from six out of the 11 cormorants sampled in 2000. The immunostaining was not as distinct as the staining patterns observed in manatees in 1996 and cormorants in 1997. Therefore, results of the modified staining procedure used on the cormorants admitted during 2000 were deemed indeterminate.

Admittance of cormorants with outbreak-specific clinical signs was positively correlated with simultaneously increased levels of *K. brevis* (cells/L) in the local marine system ($R_{xy} = 0.177$, $P = 0.0223$). The positive correlation between outbreaks in cormorants and *K. brevis* levels was more apparent with time delays of 2 through 10 wk with the stron-

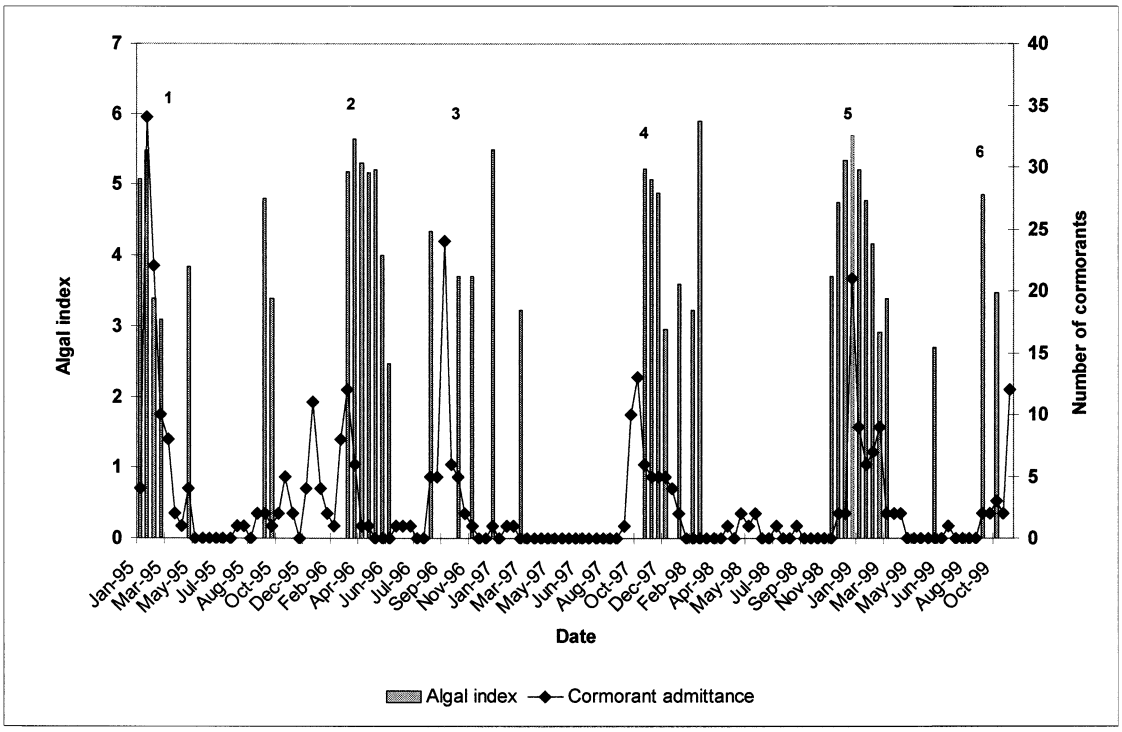

Figure 1. Double-crested cormorant admittance to a Sanibel Island wildlife clinic with outbreak-specific clinical signs correlated with 8-wk time-lagged values of the local algal index from 1995 to 1999. The six outbreaks in cormorants are labeled as 1–6.

gest correlation detected when *K. brevis* levels lagged behind cormorant admittances by 8 wk ($R_{xy} = 0.311$, $P = 0.0002$) (Fig. 1). Time lags of greater than 10 wk did not produce statistically significant cross-correlations. Overall, there were six major blooms of *K. brevis* around Sanibel Island from 1995 to 1999, demonstrated by consecutive measurements of at least 100,000 cells/L over a 6 wk period when levels were measured. Also, there were six major outbreaks in cormorants, which were demonstrated by the admittance of two or more cormorants with outbreak-specific clinical signs per 2 wk interval for a minimum of 6 wk (Fig. 1).

DISCUSSION

The clinical finding of severe cerebellar ataxia in affected cormorants admitted during all six outbreaks from 1995 through 1999 suggests a common etiology. Neurologic abnormalities in affected cormorants were consistent with exposure to a neurotoxin, although other toxic etiologies may be compatible with the observed clinical and pathologic features of these outbreaks. Similar neurologic abnormalities (incoordination and loss of righting reflex) have been observed in distressed manatees during *K. brevis* blooms.[2,11] Ataxia and spastic movements were also observed in ducklings experimentally exposed to brevetoxin.[8] The combination of the clinical signs observed in cormorants (truncal ataxia, broad-based stance, head tremors, and vertical nystagmus) suggests localized cerebellar disease. Preferential uptake of brevetoxin by the cerebellum has been noted after the experimental administration of brevetoxin to mice (Baden, pers. comm.). The spontaneous recovery of admitted cormorants is also consistent with a toxic etiology. Because toxic insults to the central nervous system can be pharmacologically mediated, clinical signs resulting from toxin exposure may be reversible once exposure to the toxin has ended. Cormorants with outbreak-specific signs had a greater probability of being released than did cormorants admitted for other reasons over this 5-yr period because of the spontaneous resolution of the clinical signs. However, a potential bias in comparing these two groups is that cormorants that were too moribund to exhibit outbreak-specific clinical signs may have been included in the control comparison group, subsequently biasing this group toward a lower re-

leased proportion. Interestingly, recovered cormorants banded before release from CROW during red tide events have been readmitted to the clinic with cerebellar ataxia as soon as 5 days after release, suggesting that there may be rapid recrudescence of clinical signs either after subsequent reexposure or as a delayed consequence of previous exposure.

The role of brevetoxin exposure in these outbreaks is supported by the histopathologic findings, which were generally mild and nonspecific even in severely debilitated cormorants. The lack of histopathologic lesions in the nervous tissue despite severe neurologic deficits in cormorants supports a neurotoxicity that produces clinical signs by a mechanism other than through direct tissue damage. The predominant histopathologic finding of multiorgan hemosiderosis in cormorants was also observed in manatees with brevetoxicosis.[2] This finding suggests a chronic, ongoing hemolytic process causing excessive destruction of the erythrocytes. These pathologic changes have been suggested to occur after weeks or even days of inhalation or ingestion of brevetoxin at subacute concentrations.[2] Multiorgan hemosiderosis has also been documented in marine and freshwater fish after exposure to brevetoxin.[12] The histopathologic findings noted in cormorants are, therefore, consistent with that observed in other species suffering from long-term exposure to brevetoxin.

Clinical evaluation of cormorants affected by the outbreaks also provides further evidence for chronic disease. Mean differences in body weight, PCV, and TS values among the outbreak cormorants and the selected control comparison group were not biologically or statistically significant. For both groups, anemia, hypoproteinemia, and mean body weight below normal were common clinical findings. Clinical findings related to chronic disease may also be common in birds brought to the rehabilitation center. For cormorants with outbreak-specific clinical signs, it is impossible to determine whether the evidence for chronicity is primary, resulting directly from chronic exposure to brevetoxin, or secondary, resulting from an acute exposure and subsequent inability to function normally. The overall low release rate observed in all cormorants admitted reflects the poor prognosis associated with chronic disease in rehabilitated birds, regardless of the etiology.

The main histopathologic finding in manatees with brevetoxicosis was moderate to severe pulmonary congestion and catarrhal rhinitis, which was consistent with an inhaled acute exposure.[2] The presence of only very mild pulmonary congestion in cormorants and the absence of pathologic lesions in tracheal tissues from all cormorants examined suggest that acute exposure through inhalation is not the primary pathogenic mechanism. Although positive brevetoxin immunostaining in the lung and tracheal tissues of the cormorants examined in 1997 supports inhalation as one route of exposure, additional routes of exposure may be important in cormorants. Because of their lack of foraging experience, immature cormorants may be more inclined to ingest the dying or dead brevetoxin-contaminated fish that are a common occurrence during red tides. Therefore, our observation that immature cormorants were significantly more likely to be admitted with brevetoxicosis than were adult cormorants supports the hypothesis that exposure to brevetoxin may be through ingestion of contaminated fish. Exposure to brevetoxin through inhalation would most likely affect all ages of birds equally. It is also possible that juveniles are more susceptible to the effects of brevetoxin or are more likely to be admitted to a rehabilitation center once intoxicated. Because cormorants are a top predator and consume primarily large fish, this species may be exposed to unusually high doses of brevetoxin if biomagnification of brevetoxin occurs in the food web as it occurs with other toxins.[7,15,16] This may explain why outbreaks of the magnitude observed in cormorants have not been noted in other fish-eating marine birds.

The positive immunostaining in tissues from the four cormorants sampled during the 1997 outbreak confirms the uptake of brevetoxin in this species, but documenting an association among brevetoxin uptake, cellular pathology, and clinical disease requires further refinement of the analytic techniques. The immunohistochemical staining technique has not yet been validated in birds, and the disparate results in cormorants admitted during two different *K. brevis* blooms are difficult to interpret in the light of an unknown sensitivity and specificity for the test. The indeterminate results in birds sampled in 2000 may be caused by the modification in the technique to reduce background staining or improper sample handling. Because brevetoxin clearance from tissues occurs at an unknown rate, the timing of sampling relative to exposure may have also affected the staining results. A major limitation of this test is that it does not differentiate between exposure significant enough to cause clinical signs and subclinical baseline exposure after an algal bloom, which would be expected in fish-eating marine birds.

The significant positive correlation between the timing of *K. brevis* blooms and the subsequent admittance of cormorants with outbreak-specific clin-

ical signs supports a cause and effect relationship between these two events. The time delay ranging from 2 to 10 wk is reasonable, given that *K. brevis* measured in cells per liter is only an approximate estimate of the potential for brevetoxin exposure. Brevetoxin concentration increases after *K. brevis* blooms reach a stationary phase because of dinoflagellate cell death and subsequent toxin release. Brevetoxin may remain in water and in prey items long after *K. brevis* algae are measurable by current methods. Shellfish have been shown to remain toxic for 75–300 days after a *K. brevis* bloom has dissipated.[5,13] The time delay is also consistent with the clinicopathologic features of this disease, which suggests that cormorants most likely experience a chronic and cumulative detrimental effect from exposure.

Without experimental trials, a cause and effect relationship for some toxic etiologies that do not consistently cause pathologic lesions may only be demonstrated by a synthesis of circumstantial evidence. Harmful algal blooms may affect cormorants through a variety of indirect mechanisms. Most notably, the large fish kills associated with *K. brevis* blooms may deplete food resources, rendering cormorants more susceptible to other disease processes. Thus, it is possible that *K. brevis* blooms are only indirectly related to cormorant morbidity and that brevetoxin is not the actual etiologic agent for the periodic epidemics documented here. However, the direct association between the timing of the algal blooms and the cormorant epidemics with an appropriate time delay is convincing when interpreted in conjunction with the histopathologic findings and the specific neurologic clinical signs observed in affected cormorants.

The high proportion of cormorants admitted with brevetoxicosis-specific clinical signs to this rehabilitation center suggests that brevetoxin exposure may be a substantial cause of morbidity and mortality in cormorants in this area of southwest Florida. Rigorous validation of an immunohistochemical technique with positive and negative controls for use in birds is necessary to compare brevetoxin uptake in symptomatic cormorants with baseline levels in asymptomatic cormorants. Similarly, brevetoxin-specific tests, adapted for use in other marine animals, would permit the detection of sublethal brevetoxin effects in other species, which is the first step in understanding the true ecosystem-level impacts of *K. brevis* blooms in the Gulf of Mexico.

Acknowledgments: We thank Dr. P. J. Deitschel, Anita Pinder, David Allen, and Margot White for their assistance with the data and the sample collection at the Clinic for the Rehabilitation of Wildlife. We also thank Drs. Earnest Truby and Karen Steidinger at the Florida Marine Research Institute for sharing the data on the temporal distribution of local *K. brevis* concentration. The Florida Marine Research Institute, the U.S. Coast Guard, Mote Marine Laboratory, Rookery Bay National Estuarine Reserve, the University of South Florida, the City of Sanibel, Lee County Natural Resources Department, Shellfish Environmental Assessment Section, and the National Oceanic and Atmospheric Administration collaborated to collect samples to assess local *K. brevis* concentration. We also thank Drs. Kim Miller, Rebecca Cole, and David Jessup for their guidance in clinically evaluating these outbreaks in cormorants.

LITERATURE CITED

1. Baden, D. G., L. E. Fleming, and J. A. Bean. 1995. Marine toxins. Handb. Clin. Neurol. 21(65): 141–175.

2. Bossart, G. D., D. G. Baden, R. Y. Ewing, B. Roberts, and S. D. Wright. 1998. Brevetoxicoses in manatees (*Trichechus manatus latirostris*) from the 1996 epizootic: gross, histologic, and immunohistochemical features. Toxicol. Pathol. 26: 276–282.

3. Box, G. E. P., and G. M. Jenkins. 1976. Time Series Analysis: Forecasting and Control. Holden-Day, San Francisco, California.

4. Burkholder, J. M. 1998. Implications of harmful microalgae and heterotrophic dinoflagellates in management of sustainable marine fisheries. Ecol. Appl. 8: S37–S62.

5. Dickey, R., E. Jester, R. Granade, D. Mowdy, C. Moncreiff, D. Rebarchik, M. Robl, S. Musser, and M. Poli. 1999. Monitoring brevetoxins during a *Gymnodinium breve* red tide: comparison of sodium channel specific cytotoxicity assay and mouse bioassay for determination of neurotoxic shellfish toxins in shellfish extracts. Nat. Toxins 7: 157–165.

6. Epstein, P. B., B. H. Sherman, E. Spanger-Siegfried, A. N. Langston, S. Prasad, and B. McKay. 1998. Marine ecosystems: emerging diseases as indicators of change. Year of the Ocean Special Report on Health of the Oceans from Labrador to Venezuela. Health Ecological and Economic Dimensions of Global Change Program, Center for Health and the Global Environment, Harvard Medical School, Boston, Massachusetts. Pp. 1–85.

7. Fisher, S. W. 1995. Mechanisms of bioaccumulation in aquatic systems. *In:* Ware, G. (ed.). Reviews of Environmental Contamination and Toxicology. Springer-Verlag, New York. Pp. 87–117.

8. Forrester, D. J., J. M. Gaskin, F. H. White, N. P. Thompson, J. A. Quick, G. E. Henderson, J. C. Woodard, and W. D. Robertson. 1977. An epizootic of waterfowl associated with a red tide episode in Florida. J. Wildl. Dis. 13: 160–167.

9. Geraci, J. R. 1989. Clinical Investigation of the 1987–1988 Mass Mortality of Bottlenose Dolphins Along the U.S. Central and South Atlantic Coast. Final Report.

National Marine Fisheries, U.S. Navy (Office of Naval Research) and Marine Mammal Commission, Washington, D.C. Pp. 1–63.

10. Gunter, G., R. H. Williams, C. C. Davis, and F. G. Walton Smith. 1948. Catastrophic mass mortality of marine animals and coincident phytoplankton bloom on the west coast of Florida, November 1946 to August 1947. Ecol. Monogr. 18: 309–324.

11. O'Shea, T. J., G. B. Rathbun, R. K. Bonde, C. D. Buergelt, and D. K. Odell. 1991. An epizootic of Florida manatees associated with a dinoflagellate bloom. Mar. Mamm. Sci. 7: 165–179.

12. Quick, J. A., and G. E. Henderson. 1974. Effects of *Gymnodinium breve* red tide on fishes and birds: a preliminary report on behaviour, anatomy, hematology, and histopathology. Proc. Gulf Coast Reg. Symp. Dis. Aquat. Anim. 85–113.

13. Steidinger, K. A., P. Carlson, D. Baden, C. Rodriguez, and J. Seagle. 1998. Neurotoxic shellfish poisoning due to toxin retention in the clam *Chione cancellata*. Eighth International Conference on Harmful Algae, 1998; Vigo, Spain.

14. Steidinger, K. A., and H. L. Penta Melton. 1999. Harmful Microalgae and Associated Public Health Risks in the Gulf of Mexico. U.S. Environmental Protection Agency: Gulf of Mexico Program. Florida Marine Research Institute, St. Petersburg, Florida.

15. Suedel, B. C., J. A. Boraczek, R. K. Peddicord, P. A. Clifford, and T. M. Dillon. 1994. Trophic transfer and biomagnification potential of contaminants in aquatic ecosystems. *In:* Ware, G. (ed.). Reviews of Environmental Contamination and Toxicology. Springer-Verlag, New York. Pp. 21–86.

16. Walker, C. H. 1990. Persistent pollutants in fish-eating sea birds—bioaccumulation, metabolism, and effects. Aquat. Toxicol. 17: 293–324.

17. Walker, S. T. 1884. Fish mortality in the Gulf of Mexico. Proc. U.S. Natl. Mus. 6: 105–109.

Received for publication 2 July 2001